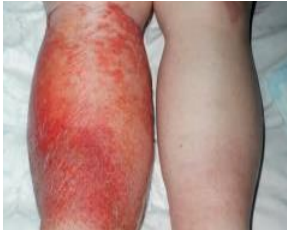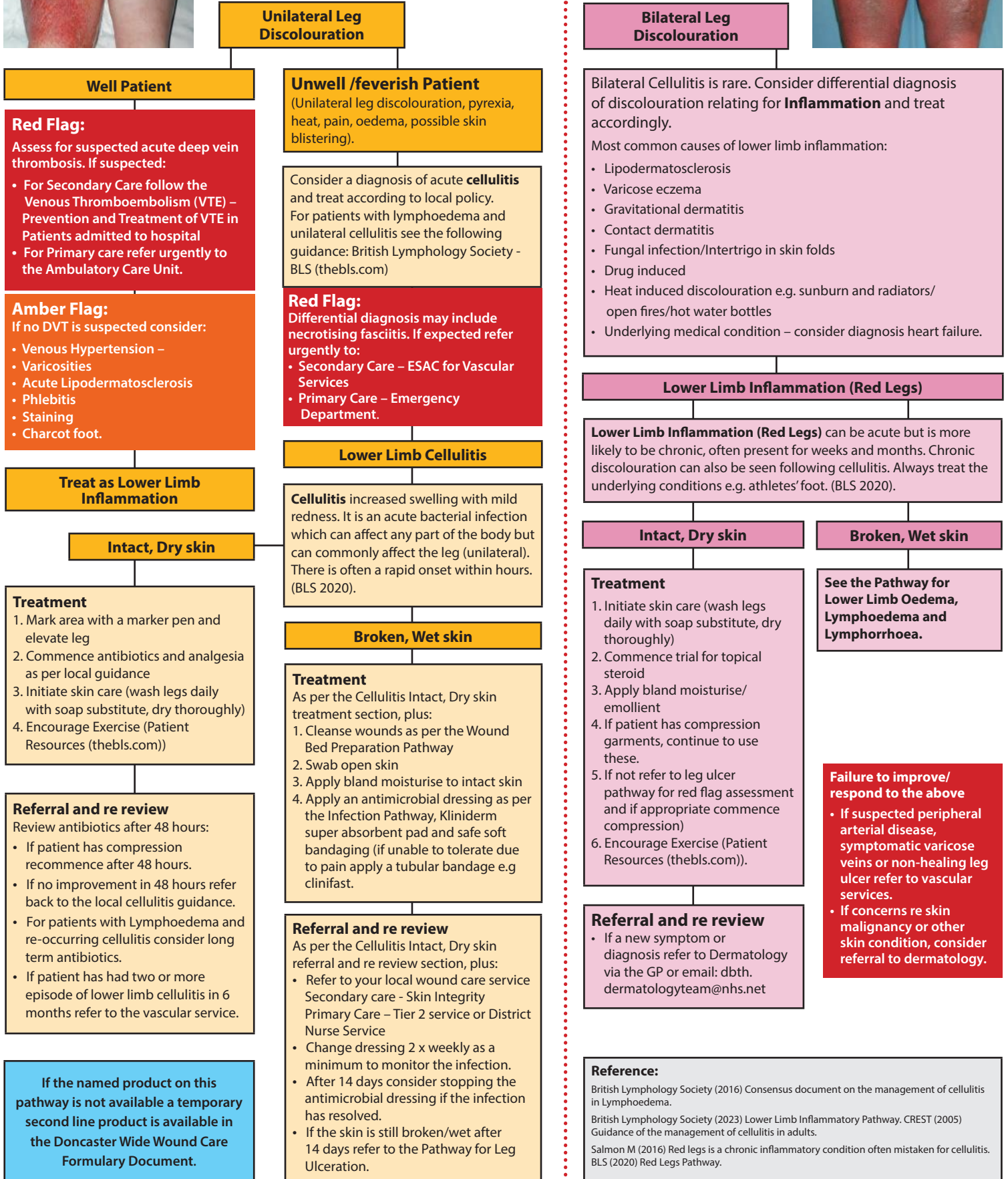

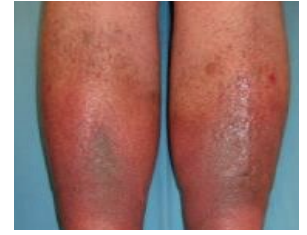
# Guidance for identifying Cellulitis or Red Legs



Inflammatory or cellulitis skin colour changes may differ in presentation depending on skin tones. It is vital that clinicians are familiar with skin tone and texture changes to ensure accurate diagnosis and care (Wounds UK, 2021).



If the named product on this pathway is not available a temporary second line product is available in the Doncaster Wide Wound Care Formulary Document.

**Reference:**  
 British Lymphology Society (2016) Consensus document on the management of cellulitis in Lymphoedema.  
 British Lymphology Society (2023) Lower Limb Inflammatory Pathway. CREST (2005) Guidance of the management of cellulitis in adults.  
 Salmon M (2016) Red legs is a chronic inflammatory condition often mistaken for cellulitis. BLS (2020) Red Legs Pathway.